

# Structural Brain Imaging of Attention-Deficit/Hyperactivity Disorder

Larry J. Seidman, Eve M. Valera, and Nikos Makris

*Many investigators have hypothesized that attention-deficit/hyperactivity disorder (ADHD) involves structural and functional brain abnormalities in frontal-striatal circuitry. Although our review suggests that there is substantial support for this hypothesis, a growing literature demonstrates widespread abnormalities affecting other cortical regions and the cerebellum. Because there is only one report studying adults with ADHD, this summary is based on children. A key limitation of the literature is that most of the studies until recently have been underpowered, using samples of fewer than 20 subjects per group. Nevertheless, these studies are largely consistent with the most comprehensive and definitive study (Castellanos et al 2002). Moreover, studies differ in the degree to which they address the influence of medications, comorbidities, or gender, and most have not addressed potentially important sources of heterogeneity such as family history of ADHD, subtype, or perinatal complications. Despite these limitations, a relatively consistent picture has emerged. The most replicated alterations in ADHD in childhood include significantly smaller volumes in the dorsolateral prefrontal cortex, caudate, pallidum, corpus callosum, and cerebellum. These results suggest that the brain is altered in a more widespread manner than has been previously hypothesized. Developmental studies are needed to address the evolution of this brain disorder into adulthood.*

**Key Words:** Attention-deficit/hyperactivity disorder, structural brain imaging, MRI

Most of what we know about attention-deficit/hyperactivity disorder (ADHD) has come from studies of children. Nonetheless, over the past decade, adult ADHD has gradually become recognized as a valid and reliable disorder that shares many features with the childhood form (Faraone et al 2000). Approximately 30%–60% of individuals diagnosed with ADHD in youth have symptoms that persist into adulthood (Biederman 1998, 2000). Adults with ADHD share similar clinical features, comorbidities, neuropsychologic deficits, and failures in major life domains with ADHD children (Faraone et al 2000; Hechtman 1992; Mannuzza et al 1993; Weiss and Hechtman 1986). Because ADHD is a developmental disorder, to gain a full understanding of brain structure in adult ADHD, knowledge gained from children must be integrated (Castellanos 1997). Practically speaking, we know little about the neuroanatomy of ADHD in adults; whereas there are 27 published quantitative reports of structural neuroimaging findings in ADHD children from more than a dozen research groups, there is only one published structural imaging study of adults. Thus, we focus on studies of children and use them as a foundation to understand potential structural abnormalities in adults.

From the Pediatric Psychopharmacology Unit (LJS, EMV) and Psychiatric Neuroscience Program (LJS, EMV), Massachusetts General Hospital; Commonwealth Research Center (LJS), Laboratory of Neuropsychology (LJS), and Laboratory of Psychiatric Epidemiology and Genetics (LJS), Massachusetts Mental Health Center; Departments of Psychiatry (LJS, EV) and Neurology and Radiology Services (NM), Harvard Medical School; Center for Morphometric Analysis (NM), Massachusetts General Hospital, Boston, Massachusetts.

Address reprint requests to Larry J. Seidman, Ph.D., Pediatric Psychopharmacology Program, Department of Psychiatry, Massachusetts General Hospital, 15 Parkman Street, WACC 725, Boston, MA 02114; E-mail: larry\_seidman@hms.harvard.edu.

Received June 2, 2004; revised October 28, 2004; accepted November 6, 2004.

## Historical Background for Hypotheses of Brain Dysfunctions in ADHD

Attention-deficit/hyperactivity disorder was first described 100 years ago as a childhood disorder found mainly in boys, initially called “hyperactivity,” or “hyperkinesis disorder of childhood” (Still 1902). In the 1960s, the (now outmoded) terms “minimal brain damage” or “minimal brain dysfunction” (MBD) were used to suggest this could be a brain disorder. Revisions in the diagnostic construct have been made a number of times over the past century. The most significant shift occurred in the 1970s, when the concept of attention dysfunction was introduced as the central defining feature (Douglas 1972). The key symptoms needed for the diagnosis, however, were behavioral descriptions of motor and attentional problems rather than direct cognitive measures of inattention. Nevertheless, the renaming of the disorder and the subsequent focus on “attention” led to a range of neuropsychologic and neurobiological hypotheses regarding the etiology and pathophysiology of ADHD within a more specific brain localization perspective (Barkley 1997; Mattes 1980) than the earlier concept of “MBD.” Moreover, these hypotheses were linked to advances in understanding the neurologic bases of attention (Mesulam 1990; Posner and Petersen 1990).

The diagnosis of ADHD is currently made on the basis of developmentally inappropriate symptoms of inattention, impulsivity, and motor restlessness (American Psychiatric Association 1994), and three subtypes are recognized: inattentive, hyperactive-impulsive, and combined (reflecting a combination of the other two types). Symptoms must be 1) observed early in life (before age 7), 2) pervasive across situations, and 3) persistent. The similarities between ADHD and those of neurologic patients suggest that ADHD is a brain disorder affecting the prefrontal cortex (Mattes 1980). Current theories emphasize the central role of attentional and executive dysfunctions in children (Barkley 1997; Pennington and Ozonoff 1996). Early support for the “prefrontal” or “frontostriatal” model also came from the success of stimulant medications, as well as from animal models implicating dopamine pathways (Shaywitz et al 1978), that have a strong predilection for prefrontal cortex. As neurocognitive models of ADHD have become more refined, one particular executive process, inhibition, is hypothesized to be a core deficit

(Barkley 1997; Pennington and Ozonoff 1996). Depending on the kind of inhibitory task used, abnormalities may be largely associated with either the right prefrontal cortex (Stop-Signal Task; Aron et al 2003) or the anterior cingulate cortex (Stroop-type tasks; Bush et al 2003). Thus, neurocognitive models have played a major role in hypothesis generation regarding alterations of neuroanatomy in ADHD (Seidman et al 2004a, 2004b).

### Structural Brain Imaging in Children and Teenagers with ADHD

There are a number of previous reviews of structural and functional imaging studies of ADHD (Castellanos 1997; Durston 2003; Seidman et al 2004a). This article differs from previous reviews by providing a comprehensive table summarizing the results by anatomic region, proposing in some detail the importance of the cerebellum in ADHD, and providing a critical analysis of structural imaging studies. This review is based on a search through computer data bases, using key words such as “structural brain abnormalities,” “magnetic resonance imaging” (MRI), and “ADHD,” as well as a review of the references in all published papers and reviews we obtained. Only quantitative studies are reviewed.

Most of the studies assessed boys between the ages of 4 and 18, but the few studies that also include girls are largely consistent with findings on boys (e.g., Castellanos et al 2001, 2002). The primary technique for measuring brain structure in living people is MRI. Although there are a few computerized tomography (CT) studies published prior to 1990 when MRI studies on ADHD began to emerge, CT has substantially poorer spatial resolution than MRI and will not be covered. Most of the structural MRI studies used region of interest (ROI) methods to measure volumes, and the results of these are summarized and compared with those observed using automated voxel-based morphometry (VBM) or surface density techniques. We summarize the findings in detail in Table 1.

### Theoretically Chosen Brain Regions of Interest

#### Total and Lateralized Cerebral Volume

Seven of twelve reports (Castellanos et al 1996, 2001, 2002; Filipek et al 1997; Kates et al 2002; Mostofsky et al 2002; Hill et al 2003) have shown that in ADHD children through age 19, the total cerebrum, particularly the right hemisphere, is 3%–5% smaller, and one study reported reduced intracranial volume (Durston et al 2004). Studies have also reported smaller total gray and white matter (Castellanos et al 2002; Mostofsky et al 2002). No study reported significantly larger volumes.

#### Prefrontal Cortex (PFC)

The frontal cortex can be divided into five major functional subdivisions: the prefrontal (orbital, dorsolateral, and mesial), premotor, and motor regions (Fuster 1989): Orbital frontal (OF) lesions are associated with social disinhibition and impulse dyscontrol; dorsolateral prefrontal (DLPFC) lesions are associated with organizational, planning, working memory, and attentional dysfunctions; and mesial lesions are linked with dysfluency and slowing of spontaneous behaviors. Motor and premotor cortices are involved in elemental and sequential motor movements, respectively. Prefrontal hypotheses of ADHD have primarily involved DLPFC and OF. Some investigators (Cohen et al 1994) have hypothesized that the ability to maintain context relies on dopaminergic tone in DLPFC, a putative neuromodulator disturbance in ADHD. Others (Barkley 1997)

have suggested that behavioral inhibition may be associated with OF dysfunction as well.

All of the studies measuring at least one compartment of PFC reported smaller volumes in ADHD. Nine ROI MRI reports of ADHD children (Castellanos et al 1996, 2001, 2002; Durston et al 2004; Filipek et al 1997; Hill et al 2003; Hynd et al 1990; Kates et al 2002; Mostofsky et al 2002) identified smaller prefrontal volumes in areas corresponding to the DLPFC, either in the right or left hemisphere. Overmeyer et al (2001), using VBM, showed a reduction in right superior frontal gyrus volume. Sowell et al (2003) reported reduced brain surface extent in inferior portions of DLPFC bilaterally using automated, computational image analyses.

#### Dorsal Anterior Cingulate Cortex (dACC)

The dACC, lying on the medial surface of the frontal lobe, has strong connections to the DLPFC. The dACC is considered to play a critical role in complex cognitive processing (Bush et al 2000), particularly target detection, response selection, error detection, and reward-based decision making (Bush et al 2002), functions that are thought to be impaired in ADHD. Functional neuroimaging studies on normal volunteers have shown the dACC to be activated by numerous cognitive tasks, particularly Stroop and Stroop-like cognitive interference tasks (Paus et al 1998). Although this region is theoretically important, there are no structural studies of the dACC in ADHD. One study did report significant cingulate abnormalities in brain structure in ADHD children (using a VBM method) showing a reduction in right posterior cingulate volume (Overmeyer et al 2001).

#### Corpus Callosum (CC)

The CC, composed of mostly myelinated axons, connects homotypic regions of the two cerebral hemispheres and is essential for communication between the two cerebral hemispheres. Size variations in the CC presumably reflect differences in the number or size of axons (relating to the extent of myelination) that connect these regions. Changes may also reflect differences in the number of cortical neurons within homologous regions.

Abnormalities of the CC have been reported in a number of morphometric studies of children with ADHD (Baumgardner et al 1996; Giedd et al 1994; Hill et al 2003; Hynd et al 1991; Lyoo et al 1996; Semrud-Clikeman et al 1994). Different measures were used; some studies used five subdivisions in O’Kusky’s method (O’Kusky et al 1988), and others used the seven subdivisions in Witelson’s (1989) approach, so the results are not easily compared. Nevertheless, fairly consistent evidence indicates that abnormalities in children with ADHD are found particularly in the posterior regions linked to temporal and parietal cortices in the splenium (Lyoo et al 1996; Hill et al 2003; Hynd et al 1991; Semrud-Clikeman et al 1994).

#### Basal Ganglia (Striatum)

The caudate, putamen, and globus pallidus (i.e., the pallidum) are part of discrete, somatotopically distributed circuits essential for executive functions. These circuits include prefrontal–basal ganglia–thalamic loops (Alexander et al 1986). Damage to the striatum is plausibly associated with the etiology of ADHD (Lou 1996). First, because it is located at a border zone of arterial supply and is exposed to circulatory compromise, the striatum is vulnerable to perinatal hypoxic complications (which occur at higher than normal rates in ADHD; Sprich-Buckminster et al 1993). Second, experimental striatal lesions in animals produce

**Table 1.** Structural MRI Findings in Persons with Attention-Deficit/Hyperactivity Disorder Compared with Normal Control Subjects

ROI	Positive Findings <sup>a</sup>	Negative Findings <sup>b</sup>	Comments
Total Brain Volume	9, 11, ( $p < .10$ ) <sup>c</sup> , 18, 19, 21, 22 ( $p < .07$ ) <sup>c</sup> , 25	1, 10, 20, 24, 28 (L & R),	<sup>c</sup> Studies 11 and 22 had small samples and showed nonsignificant trends. In 11, ADHD subjects had 5% volume reduction, comparable to 9. In 22, ADHD subjects had 6% volume reduction.
Intracranial volume	28		
Total cerebral WM	11 <sup>c</sup> ( $p < .09$ ), 19, 21	28 (bilateral)	Study <sup>c</sup> 11 has small sample.
Total cerebral GM	19, 21	28 (bilateral)	
Corpus Callosum (CC)			Studies 2 and 8 used the O'Kusky method, which names the most anterior section the genu, and the posterior part the splenium, and then divides the remaining areas into three equal size regions. Studies 4, 6, 10, and 25 used the Witelson method, which divides the CC into 7 areas, with the rostrum being names and anterior region. Thus, region and actual boundaries differ somewhat and are not directly comparable. Study 15 is not included in the table because the comparison group was composed of siblings of children with ADHD.
Total	25		
1. Rostrum	6	4, 8, 10, 25	
2. Genu	2	4, 6, 10, 25	
3. Rostral body	6, 8	4, 10, 25	
4. Anterior midbody	2	4, 6, 10, 25	
5. Posterior midbody		4, 6, 10, 25	
6. Isthmus	10	4, 6, 25	
7. Splenium	2, 4, 10, 25	6, 8	
Frontal Lobe	1 (R), 18 (L)	1 (L), 18 (R), 21 (total), 22 (total)	Study 1 used area measurements.
Prefrontal cortex (PFC)	21 (total), 22 (L, R)		When Bonferroni corrected, 22 was no longer significant.
"Anterior PFC"	9, 11 (R), 11 (L, $p < .06$ ) <sup>c</sup>		<sup>c</sup> 11 had small samples (< 20 per group) and showed trends.
PFC GM	21 (total bilateral) 22, 28 (R)	22 (bilateral), 28 (L)	
Superior PFC	17, 25 (R), 25 (total)	25 (L)	Study 17 uses voxel-based morphometry.
Inferior PFC		25 (total)	
Frontal GM	19, 21 (bilateral)	21 (total)	
PFC WM	21 (total, bilateral) 22 (total)	22 (bilateral), 28 (bilateral)	When Bonferroni corrected, 22 was no longer significant.
Frontal WM	19, 21 (L)	21 (total), 21 (R)	
Frontal deep WM	21 (total and bilateral)		
Orbitofrontal cortex	20 (L)	20 (R)	
Premotor cortex	21 (total)	22 (total)	
Premotor GM	21 (total and bilateral)		
Premotor WM	21 (L)	21 (total & R)	
Precentral cortex		22 (total)	
Frontal motor		21 (total)	
Cingulate cortex	17 (posterior)	21 (anterior), 22 (total)	
Temporal Lobe	26 <sup>c</sup>	9 (L, R), 21	<sup>c</sup> Study 26, anterior is smaller, posterior is larger
GM	19	28 (bilateral), $p < .06$	
WM	19	28 (bilateral)	
Planum temporale		1 (L, R)	
Insula		1, 11 (L, R)	
Parietal Lobe	26	21	Study 26, significantly larger in ADHD.
GM	19	28 (bilateral, $L p < .07$ )	
WM	19	28 (bilateral), $L p < .07$ )	
Occipital Lobe	26	21	Study 26, significantly larger in ADHD.
GM	19, 28 (L)	28 (R)	
WM	19, 28 (L)	28 (R)	
Posterior Area of Cortex	Smaller 11 ( $p < .07$ ) <sup>c</sup> (bilateral)	1	<sup>c</sup> Study 11 has small sample.
Amygdala		9, 11 (L & R)	
Hippocampus		9, 11 (L & R)	
Caudate			
Head	3, 4 (L), 12 (R), 18 (bilateral), 19 (total)	12 (L), 3, 11 (R), 23–25 (bilateral), 24–25 (total)	
Total (head + body)	11 (L), 5, 9 (R), 27	5, 7, 9 (L), 7, 11 (R)	Studies 5, 9 (essentially same large sample, 2-mm-slice thickness), study 27 compares monozygotic twins discordant for ADHD.
Pallidum	7, 9, 18 (L), 9, 17 (R)	7, 18 (R)	
Putamen	17	7, 9 (L & R)	
Lateral Ventricles			
Anterior		10 (bilateral)	
Posterior	10 (bilateral)		

**Table 1.** Continued

ROI	Positive Findings <sup>a</sup>	Negative Findings <sup>b</sup>	Comments
Total		9, 11	
Cerebellum (Total)	9 (bilateral), 18 (R), 19, 28 (R)	18 (L), 28 (L), 25	The cerebellum was the only region that remained statistically significant after controlling for total cerebral volume and Vocabulary in study 19.
Vermal volume (midsagittal)	13	18	
Anterior vermis—Lobes I–V	25	13, 14	
Posterior superior Vermis—Lobes VI–VII	24 (total), 24 (L),	13, 14, 24 (R), 25	
Posterior inferior Vermis—lobes VI–VII	18		
Posterior inferior Vermis—lobes VIII–X	13, 14, 24 (total), 24 (L), 18, 25	24 (R)	
Anterior lobe		24 (total and bilateral)	

ADHD, attention-deficit/hyperactivity disorder; bilateral, left and right analyzed separately; GM, gray matter; L, left side of brain; MRI, magnetic resonance imaging; R, right side of brain; ROI, region of interest; Total, left and right hemispheres combined; WM, white matter.

References for table: 1) Hynd et al (1990); 2) Hynd et al (1991); 3) Hynd et al (1993); 4) Semrud-Clikeman et al (1994); 5) Castellanos et al (1994); 6) Giedd et al (1994); 7) Aylward et al (1996); 8) Baumgardner et al (1996); 9) Castellanos et al (1996); 10) Lyoo et al (1996); 11) Filipek et al (1997); 12) Mataro et al (1997); 13) Berquin et al (1998); 14) Mostofsky et al (1998); 15) Overmeyer et al (2000); 16) Nopolous et al (2000); 17) Overmeyer et al (2001); 18) Castellanos et al (2001); 19) Castellanos et al (2002); 20) Hesslinger et al (2002); 21) Mostofsky et al (2002); 22) Kates et al (2002); 23) Pineda et al (2002); 24) Bussing et al (2002); 25) Hill et al (2003); 26) Sowell et al (2003); 27) Castellanos et al (2003); 28) Durston et al (2004)

Only results from quantitative MRI studies presented in the table (not including Nopolous et al 2000) Only statistically significant results ( $p \leq .05$ ) presented as positive, except for trends which are noted. Small sample size was defined as 20 subjects or fewer per group (including studies 1–4, 6–8, 10–12, 14–15, 17, 20–24, 27).

<sup>a</sup>In all significant comparisons, ADHD subjects had smaller volumes, except study 26 (Sowell et al 2003).

<sup>b</sup>No difference in volumes.

<sup>c</sup> $p < .10$  in small-sample-size studies.

hyperactivity and poor performance on working memory and response inhibition tasks (Alexander et al 1986). Third, the striatum is one of the richest sources of dopaminergic synapses (Dougherty et al 1999), and dopamine is important in the regulation of striatal functions. Finally, stimulant medications, commonly used to treat ADHD, have effects on striatum (Volkow et al 2002).

A growing body of brain-imaging evidence supports a role for the basal ganglia in ADHD. Nine of thirteen studies (69%) have shown significantly smaller caudate total or the head alone, either on the left or right side (Castellanos et al 1994, 1996, 2001, 2002; Filipek et al 1997; Hynd et al 1993; Mataro et al 1997; Semrud-Clikeman et al 1994), including smaller total caudate volumes in affected rather than unaffected monozygotic twins discordant for ADHD (Castellanos et al 2003). All four studies of the pallidum have shown children with ADHD to have smaller volumes, either on the right (Castellanos et al 1996; Overmeyer et al 2001) or the left (Aylward et al 1996; Castellanos et al 2001, 2002). In addition, an important finding was reported by Castellanos et al (2002), who demonstrated that significant differences between children with ADHD and control subjects in caudate volume diminished by the oldest age studied (19 years). This was the only region studied that showed a “normalization” of brain volume over time. This suggests that studies of ADHD adults are needed to determine the persistence and stability of anatomical changes across the life span.

### Cerebellum

Although the cerebellum has traditionally been thought to be primarily involved in motor control, both clinical and research

findings over the past 20 years have shown cerebellar involvement in a number of cognitive and affective processes. Schmahmann and Sherman (1998) coined the term “cerebellar cognitive affective syndrome” after recognizing cognitive and affective disturbances in cerebellar lesion patients. Furthermore, reviews of neuroimaging data indicate that the cerebellum is active in a number of cognitive tasks independent of motor control (Desmond and Fiez 1998). Additionally, Middleton and Strick (2001) have demonstrated cerebellar–cortical connections that provide an anatomic substrate for a cerebellar–prefrontal circuit in the pathophysiology of ADHD.

All five groups of researchers studying the cerebellum in ADHD children have observed structural abnormalities including volume reduction in specific regions of the vermis. For example, reductions in the posterior inferior lobules, VIII to X, of the cerebellar vermis have been found for both ADHD boys (Berquin et al 1998; Bussing et al 2002; Castellanos et al 1996; Hill et al 2003; Mostofsky et al 1998) and girls (Castellanos et al 2001; Hill et al 2003). Whereas Bussing and colleagues also found reductions in lobules VI–VII, other groups did not find differences. In the largest study, of 152 children and adolescents with ADHD and 139 matched control subjects, Castellanos et al (2002) found reductions in ADHD for all brain regions measured. When they adjusted for total cerebral volume, however, only the difference for the cerebellar volume remained significant. Additionally, cerebellar volumes were significantly and negatively correlated with ratings of attentional problems. Most recently, Durston et al (2004) found smaller overall right cerebellar volumes in a group of 30 ADHD children.

## Exploratory Brain Regions of Interest

A number of reports have identified abnormalities in ROIs that were not predicted by cognitive models of ADHD. Although it is too soon to know whether these results will be robust, they are important to consider, because a neurodevelopmental etiology of ADHD can account for widespread alterations in the formation of the brain that have yet to be well studied (Nopoulous et al 2000).

### Temporal Lobe

This region may be of interest in ADHD because it contains areas relevant to auditory–linguistic functioning that are considered to be abnormal in some ADHD children. Castellanos et al (2002) reported significantly reduced temporal lobe volumes. Sowell et al (2003), using computational measurements, reported reduced anterior temporal cortices bilaterally and increased posterior temporal cortices in ADHD children.

### Parietal Lobe

This region may be of interest because it contains regions relevant to attentional functioning that are considered to be important in the cognitive pathophysiology of ADHD (Posner and Petersen 1990). Castellanos et al (2002) reported significantly reduced parietal lobe volumes. Filipek et al (1997) reported a reduction in bilateral retrocallosal regions including the parietal lobe. Of note, this is opposite to that reported by Sowell et al (2003), who noted “prominent increases” in gray matter in inferior parietal cortices bilaterally. These contradictory findings may reflect measurement or sample differences.

### Occipital Lobe

This region may be of interest in ADHD because it contains regions relevant to visual processing. Castellanos et al (2002) reported significantly reduced occipital lobe volumes. Durston et al (2004) reported that the left occipital gray and white matter were reduced as much as 9% in the children with ADHD.

### Lateral Ventricles

These structures may be of interest in ADHD because they are often affected by brain damage during the perinatal period, which has been proposed to be an etiologic factor in ADHD (Lou 1996). Lyoo et al (1996) reported significantly larger posterior lateral ventricles bilaterally, while noting no difference in the anterior portion in ADHD. No significant differences were reported for the total lateral ventricles (Castellanos et al 1996; Filipek et al 1997).

### Other Regions

A few ROIs have been studied once or twice. No significant results were reported for the planum temporale (Hynd et al 1990), insula (Filipek et al 1997; Hynd et al 1990), or amygdala and hippocampus (Castellanos et al 1996; Filipek et al 1997).

## Structural Brain Imaging in Adults with ADHD

It is unclear why there is only one structural brain imaging study in adults with ADHD. Because this contrasts sharply with the literature on most psychiatric disorders (for which there are typically numerous imaging studies), we suspect that the lack of research reflects the fact that, until recently, the validity of ADHD in adulthood was questioned. As illustrated by the burgeoning literature in other areas of adults with ADHD (seen in this issue), this tendency is changing. Thus, future structural imaging studies are anticipated and should prove to be informative.

## Total Cerebral Volume (TCV)

In the only MRI study on adults with ADHD, Hesslinger and colleagues (2002) failed to find differences in total cerebral volume between 8 ADHD and 17 healthy men.

### Frontal Cortex

Hesslinger et al (2002) also used an ROI analysis to examine the OF cortex. Their rationale for assessing OF rather than DLPFC was based on the hypothesis of potential affective dysregulation in ADHD individuals. Their finding of a significant volume reduction of the left OF confirmed their hypothesis. Given the small sample size, these results are interesting, but quite preliminary and require replication.

## Are Brain Abnormalities in Childhood ADHD Accounted for by Comorbidity?

### Psychiatric Comorbidity

Children and adults with ADHD frequently have comorbid antisocial, substance abuse, mood, anxiety, or learning disorders (LDs; Biederman et al 1993). A key question is whether these disorders account for the brain abnormalities. Importantly, studies in children and adults showed that neuropsychologic deficits in ADHD remained robust after statistically adjusting for psychiatric comorbidities (Faraone et al 2000; Seidman et al 1998, 2004b). Most of the morphometric MRI studies of children with ADHD did not address psychiatric or cognitive comorbidity, nor medication status. Despite this, the results of a few studies (Aylward et al 1996; Castellanos et al 1996; Filipek et al 1997; Semrud-Clikeman et al 1994) dealing with these confounds support the idea that structural abnormalities are found in ADHD. In studies of children with ADHD but without comorbidity, significant volume reductions in the anterior frontal lobes, the caudate, and the corpus callosum were found (Filipek et al 1997; Semrud-Clikeman et al 1994). In the largest and most comprehensive studies of childhood ADHD (Castellanos et al 1994, 2002; Giedd et al 1994), results remained significant after adjusting statistically for comorbidities and when subjects with LDs were removed from analyses. Importantly, Castellanos et al (2002) studied a substantial number of subjects with ADHD who were medication naïve, and demonstrated that morphometric findings could not be ascribed to medication exposure. Thus, the existing data suggest that at least some brain abnormalities in ADHD are independent of psychiatric comorbidity and medication.

An additional threat to the validity of demonstrating a neuroanatomy of ADHD comes from the frequent co-occurrence with mood disorders. In MRI studies of adults with bipolar disorders, brain abnormalities have been documented in the ventricles, thalamus, temporal lobe, hippocampus and amygdala, cerebellar volumes, and in the subcortical deep white matter and periventricular region, with an increased number of white matter hyperintensities (Bearden et al 2001). Adults with unipolar depression have been reported to have a smaller frontal lobe, cerebellum, caudate, and putamen (Drevets 2000). In contrast to MRI findings in ADHD, MRI studies of mood-disordered patients have not consistently found abnormalities in the corpus callosum or global volume reductions (Drevets 2000; Hoge et al 1999). Nevertheless, further research is needed to address the role of mood disorders on brain abnormalities in ADHD.

### Learning Disabilities

There is much research indicating that subjects with ADHD often have comorbid LDs; estimates are approximately 30%, depending on how LD is defined (Seidman et al 2001; Semrud-

Clikeman et al 1992). Because LDs such as dyslexia involve brain abnormalities, it is necessary to know which abnormalities are due to ADHD and which are due to the LD. Comorbidity has been addressed in only one small sample, early-generation MRI study (Hynd et al 1990), which found that both dyslexic and ADHD children had smaller right anterior-width measurements than did control subjects. The dyslexic children had a bilaterally smaller insular region and a significantly smaller left planum temporale than the control subjects. The dyslexia literature suggests that dyslexia manifests itself with symmetry of the plana (compared with the typical larger left asymmetry found in healthy control subjects); a larger corpus callosum, especially in the posterior third (Rumsey et al 1996); and left hemisphere structural and functional abnormalities (Galaburda et al 1985; Shaywitz 1998). Recent work has demonstrated differences from control subjects in a number of brain regions including the inferior frontal gyrus and cerebellum (Eckert et al 2003). Given the substantial overlap in brain region volumes between the two disorders, additional research with larger samples is needed to address this issue.

### Assessing the Effects of Gender on Brain Abnormalities in ADHD

Because severe behavioral disturbances are observed less frequently among ADHD girls, they may be less likely to come to the attention of health care providers (Gaub and Carlson 1997). Depending on the sampling source, ADHD is 2 to 9 times more prevalent among boys than girls. In adults, however, the ratio is closer to 1.5:1.0 (male:female; Biederman 1998). Although it is increasingly recognized that ADHD affects both genders, most of the research literature had been limited to male subjects (Gaub and Carlson 1997). Nevertheless, a growing literature indicates more similarities than differences in the core features of ADHD (Biederman et al 2002). Additionally, MRI reports that included female samples, have found comparable findings to what has been found in male subjects (Castellanos et al 2001). Nonetheless, additional brain research directly comparing male and female subjects will be important to rule out potential gender differences. These studies will need to take into account variability between sexes in brain volumes (Goldstein et al 2001) by including matched control subjects within gender.

### Heterogeneity of ADHD and Brain Abnormalities

A number of other potentially important sources of heterogeneity exist in addition to those described thus far—for example, presence or absence of family history of ADHD, inattentive versus hyperactive-impulsive symptoms, and perinatal complications. Studies indicate that as many as 57% of ADHD adults have at least one first-degree relative with ADHD (Biederman et al 1995). There is preliminary evidence that these individuals are more neuropsychologically impaired than those without a positive family history (Seidman et al 1995). The most robust functional brain abnormalities in ADHD adults were acquired on samples of adults with familial, childhood-onset ADHD (Bush et al 1999; Zametkin et al 1990). In addition, a structural MRI study of ADHD in childhood is based on a similarly acquired sample of familial ADHD (Filipek et al 1997; Semrud-Clikeman et al 1994). These data provide some support for the idea that the familial subgroup may have more reliably demonstrable brain abnormalities. Alternatively, they may lie on a more impaired end of a continuum of severity. Because of sample-size considerations, no studies have yet compared DSM-IV subgroups of persons with

ADHD inattentive versus combined type, nor evaluated the role of perinatal complications on the neuroanatomy of ADHD. These issues seem important to address because they likely account for variance in type of brain abnormalities in ADHD.

### Relationship of Brain Structure and Neuropsychologic Dysfunctions

The analysis of attention and executive functions into sub-components—and the mapping of attentional functions onto different brain regions—supports the proposition that inhibition and other executive deficits in ADHD will be associated with brain abnormalities. In children, Casey et al (1997) found that performance on three response inhibition tasks correlated only with those anatomic measures of frontostriatal circuitry observed to be abnormal in ADHD (i.e., the PFC, caudate, and pallidum, but not the putamen). The significant correlations were predominantly in the right hemisphere, supporting the role of right frontostriatal circuitry in response inhibition and ADHD. Semrud-Clikeman et al (2000) found a significant relationship between reversed caudate asymmetry and measures of inhibition and externalizing behavior. Poorer performance on sustained attention tasks was related to smaller volume of right hemispheric white matter (Semrud-Clikeman et al 2000). Castellanos et al (1996) found that full-scale IQ score correlated significantly with total brain volume and with left and right prefrontal regions. Using the same ADHD sample, researchers found that full-scale IQ correlated with cerebellar volumes (Berquin et al 1998). The area of the rostral body of the corpus callosum was significantly correlated with scores on the impulsivity/hyperactivity scale of the Conners questionnaire (Giedd et al 1994). These studies were conducted on boys with ADHD. A study of girls demonstrated that the pallidum, caudate, and prefrontal volumes correlated significantly with ratings of ADHD severity and cognitive performance (Castellanos et al 2001). The extant data, although limited, suggest that impairments on neuropsychologic measures of executive and attention dysfunction are modestly associated with abnormal brain volumes in ADHD (Castellanos et al 2002).

### Summary

In summary, many investigators hypothesize that a key brain abnormality in ADHD involves structural and functional abnormalities in frontostriatal circuitry (Castellanos 1997; Faraone and Biederman 1998). Although our review suggests that there is substantial anatomic support for this hypothesis, a growing literature indicates abnormalities in other cortical regions as well as the cerebellum. Because there is only one report of ADHD adults, we must currently rely on results in children with ADHD. A major limitation of the literature is that until recently most of the studies have been underpowered, using samples of fewer than 20 subjects per group, which suggests that meta-analysis will be useful. Thus, it is difficult to summarize the literature without relying heavily on the most comprehensive and definitive study (Castellanos et al 2002). Moreover, studies differ in the degree to which they address the influence of medications, comorbidities, or gender and have not addressed potentially important sources of heterogeneity such as presence of family history of ADHD, DSM subtype, or perinatal complications. Despite these limitations, a relatively consistent picture tends to emerge. The most replicated alterations in ADHD children include significantly smaller volumes in the DLPFC, caudate, pallidum, corpus callosum, and cerebellum. The findings of

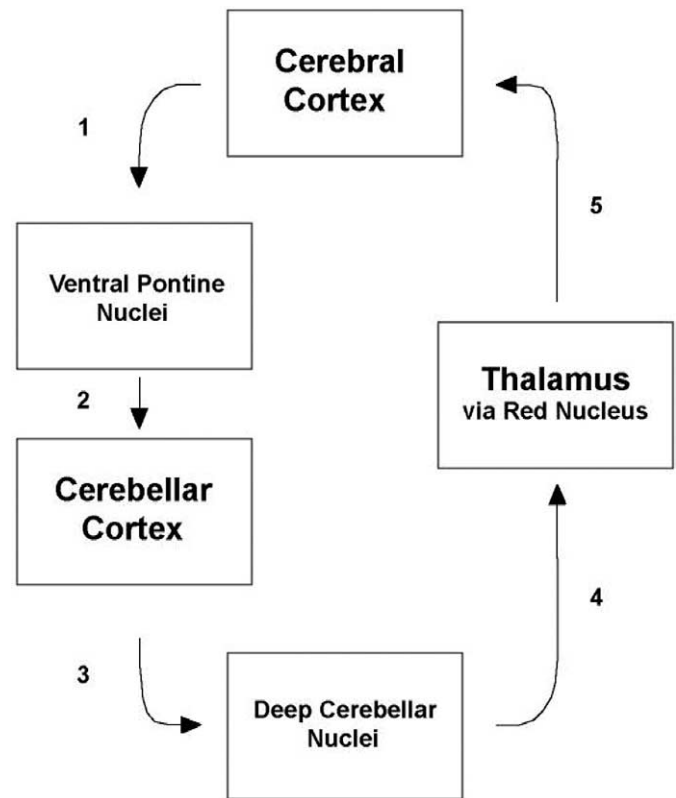
smaller total brain volumes and widespread cortical changes, however, measured with ROI techniques (Castellanos et al 2002) and automated approaches (Sowell et al 2003), suggest that the brain may be altered in a more widespread manner than has been previously hypothesized.

Another important issue for the field of anatomic neuroimaging is to gain a better understanding of the relationship of findings from largely manual, ROI-based segmentation and parcellation methods and from automated methods using VBM or other computational approaches (Sowell et al 2003). In this qualitative review, we summarized findings by anatomic region, choosing to articulate consistencies or discrepancies and reminding the reader when different types of methods were used. Voxel-based morphometry techniques have been validated in their ability to detect volumetric changes (Ashburner and Friston 2001), and because VBM is automatic, there is no human error caused by decision making about anatomic boundaries. Nevertheless, these alternative methods have not had “head-to-head” comparisons, leaving much unknown about whether they will yield substantially comparable results. Thus far, in ADHD, whereas Sowell et al (2003) reported findings in the DLPFC consistent with other investigators, results for the posterior cortex went in the opposite direction from Castellanos et al (2002). Further research is needed to reconcile the differing methodologies.

## Future Directions for Research

### Microanalysis of ROIs—Example of Cerebellar Anatomy and Connections

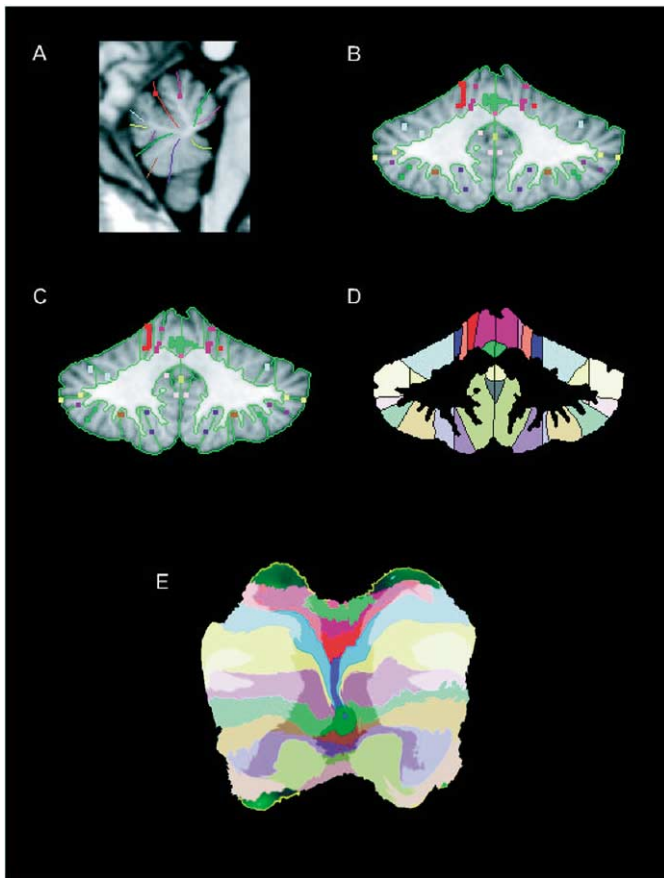
The subtle but widespread and developmentally based alterations in the brain in ADHD can be conceptualized as potentially involving dysfunctions of brain connectivity. Although it is beyond the scope of this article to address this in detail, one of the most interesting questions in ADHD is how to understand the role and relationship of cerebellar to frontostriatal abnormalities. The cerebellum is increasingly understood to be important in ADHD, and the precise measurement of cerebellar structures would be advantageous. We can begin to deal with this issue through discussing the well-known pathways and extensive connectivity between the cerebellum and prefrontal cortex as outlined by Schmahmann 2001. Shown is a schematic representation of the cerebrocerebellar circuitry (the following sections are numbered in reference to Figure 1). The cerebral cortex (including frontal, parietal, and ventromedial limbic temporal cortices) conveys perceptual, paralimbic, higher-order associative and motor information to the pontine nuclei in the ventral pons (1). These nuclei relay this information to the cerebellar cortex (2) through the pontocerebellar projection within the middle cerebellar peduncle. This part of the circuitry has been referred to as the feedforward limb of the cerebrocerebellar circuit (Schmahmann 1994). The cerebellar cortex feeds back to the cerebral cortex via the projection of the cerebellar cortex to the deep cerebellar nuclei (3), the projection of the deep nuclei to the thalamus through the red nucleus (4), and through the thalamocortical projection (5). This circuitry forms a complete loop by which the cerebral cortex interacts with the cerebellum (Schmahmann 2001). Although this circuitry represents the major connections of the cerebellum with the cerebrum, other connections have been documented such as with the hypothalamus and limbic structures including the septal nuclei, hippocampus, and amygdala (Heath 1974).



**Figure 1.** Pathways to and from the cerebellum via the pons and thalamus. The cerebral cortex conveys perceptual, paralimbic, higher-order associative and motor information to the pontine nuclei in the ventral pons (1). These nuclei relay this information to the cerebellar cortex (2) through the pontocerebellar projection within the middle cerebellar peduncle. The cerebellar cortex feeds back to the cerebral cortex via the projection of the cerebellar cortex to the deep cerebellar nuclei (3), the projection of the deep nuclei to the thalamus through the red nucleus (4), and through the thalamocortical projection (5). This circuitry forms a complete loop by which the cerebral cortex interacts with the cerebellum. Adapted from Schmahmann 1994, 2001.

### Cerebellar Parcellation

To take advantage of the increasing knowledge of cerebellar function and structure, researchers can benefit from advances in applied tools to measure the cerebellum in exquisite detail (Makris et al, *in press*). Previous studies have not been able to measure volumetrically the entire cerebellum. Such a volumetric method now exists. The method is described in detail by Makris et al (2003). We have begun to apply this method preliminarily to the MRI scans of a small number of adults with ADHD and control subjects (Seidman et al, *unpublished data*) from an ongoing study. First the cerebellum and cerebellar white matter are segmented, and then 11 principle fissures are traced. These are the precentral, preculminate, intraculminate, primary, superior posterior, horizontal, ansoparamedian, prebiventer, intrabiventer, secondary, and posterolateral fissures. In addition, the paravermian sulcus is traced. The cortex is then parcellated manually into 40 parcellation units, resulting in 12 units in each cerebellar hemisphere and 8 parcellation units in the posterior (or “true”) vermis. Finally, an automatic procedure divides the intermediate zone from the lateral zone and assigns the borders of the anterior vermis. This results in 64 final parcellation units, which can be painted onto the flattened cerebellar surface where the initial fissures were traced (see Figure 2).



**Figure 2.** Cerebellar parcellation: sections A–E depict the stages needed to create accurate magnetic resonance images. Adapted from Makris et al 2003.

### Longitudinal Studies

Although there is growing information that identifies neurobiological abnormalities in childhood and teenage years, there is still little systematic neurobiological information on ADHD in adulthood. These lacunae suggest several directions for future research regarding the pathophysiology of ADHD. First, it would be useful to conduct studies that use identical measures to assess neurobiological continuity in children and adults with ADHD. By collecting structural imaging data in both adults and children, one will be able to determine whether ADHD adults share abnormalities found in children with the disorder. Second, it would be important to evaluate a child sample longitudinally to determine whether the brain abnormalities change throughout the life cycle. There is only one study that has begun to conduct longitudinal studies of brain structure in ADHD (Castellanos et al 2002), and more research is clearly needed.

### Genes and Family Studies

There is a need to link the increasing evidence of genetic anomalies in ADHD with measures of brain dysfunction. We believe that when ADHD susceptibility genes have been discovered and confirmed, DNA-imaging resources will provide a useful means of testing hypotheses about gene–brain associations. This work could include genes such as the 7-repeat allele of the DRD4 gene and the 480 allele of the DAT gene, which have already been implicated in ADHD by several studies (Faraone et al 2005). These dopamine genes may have particular

relevance to certain brain regions altered in ADHD (e.g., the caudate) that are rich in dopamine (Dougherty et al 1999).

In another type of genetic approach, Durston et al (2004) published a pioneering study of sib pairs to assess the influence of family risk on ADHD brain morphology. Assessing 30 ADHD boys, 30 of their unaffected siblings, and 30 matched control subjects, they discovered that, with the exception of the cerebellum and intracranial volume, brain volumes that were reduced in the boys with ADHD relative to the control subjects were also reduced in the ADHD male siblings. This suggests that some brain alterations may be related to familial risk, whereas other abnormalities are linked to ADHD. More work is clearly indicated in this area. This strategy, which has been much more extensively applied in family brain studies of medial temporal lobe dysfunction in schizophrenia (Seidman et al 2003), allows an avoidance of medication confounds that tend to limit clear and definitive conclusions about the neuroanatomy of a disorder.

### Conclusion

The identification of neuroanatomic, neuropsychologic, and functional abnormalities in ADHD, as well as the interrelationship among these abnormalities, is crucial for understanding the neurobiological mechanisms involved in ADHD. Additional research on the neuroanatomy of adult ADHD is needed using high-resolution MRI, and a subsequent meta-analysis would strengthen these findings. This greater knowledge of the ADHD brain is necessary to help clarify the neurodevelopmental evolution of the disorder, treatment response, and the meaning of the disorder to patients, families, and treating clinicians.

*This work was supported by grants from NIMH (MH 62152; to LJS) and the March of Dimes Foundation. We thank Dr. George Bush, Katherine Crum, Dr. David Kennedy, Nicole Peace and John Schlerf for contributions to the manuscript. None of us have a conflict of interest in authoring this paper.*

*Aspects of this work were presented at the conference, “Advancing the Neuroscience of ADHD,” February 28, 2004, in Boston, Massachusetts. The conference was sponsored by the Society of Biological Psychiatry through an unrestricted educational grant from McNeil Consumer and Specialty Pharmaceuticals.*

- Alexander GE, DeLong MR, Strick PL (1986): Parallel organization of functionally segregated circuits linking basal ganglia and cortex. *Annu Rev Neurosci* 9:357–381.
- American Psychiatric Association (1994): *Diagnostic and Statistical Manual of Mental Disorders, 4th ed. (DSM-IV)*. Washington, DC: American Psychiatric Association.
- Aron AR, Fletcher PC, Bullmore ET, Sahakian BJ, Robbins TW (2003): Stop-signal inhibition disrupted by damage to the right inferior frontal gyrus in humans. *Nat Neurosci* 6:115–116.
- Ashburner J, Friston KJ (2001): Why voxel-based morphometry should be used. *Neuroimage* 14:1238–1243.
- Aylward EH, Reiss AL, Reader MJ, Singer HS, Brown JE, Denckla MB (1996): Basal ganglia volumes in children with attention-deficit hyperactivity disorder. *J Child Neurol* 11:112–115.
- Barkley R (1997): Behavioral inhibition, sustained attention, and executive functions: Constructing a unifying theory of ADHD. *Psychol Bull* 121:65–94.
- Baumgardner TL, Singer HS, Denckla MB, Rubin MA, Abrams MT, Colli MJ, Reiss AL (1996): Corpus callosum morphology in children with Tourette syndrome and attention deficit hyperactivity disorder. *Neurology* 47: 1–6.
- Bearden CE, Hoffman KM, Cannon TD (2001): The neuropsychology and neuroanatomy of bipolar affective disorder: A critical review. *Bipolar Disord* 3:106–150.



- Berquin PC, Giedd JN, Jacobsen LK, Hamburger SD, Krain AL, Rapoport JL, Castellanos FX (1998): Cerebellum in attention-deficit hyperactivity disorder: A morphometric MRI study. *Neurology* 50:1087–1093.
- Biederman J (1998): Attention-deficit/hyperactivity disorder: A life span perspective. *J Clin Psychiatry* 59:4–16.
- Biederman J, Faraone SV, Mick E, Spencer T, Wilens T, Kiely K, et al (1995): High risk for attention deficit hyperactivity disorder among children of parents with childhood onset of the disorder: A pilot study. *Am J Psychiatry* 152:431–435.
- Biederman J, Faraone SV, Spencer T, Wilens T, Norman D, Lapey KA, et al (1993): Patterns of psychiatric comorbidity, cognition, and psychosocial functioning in adults with attention deficit hyperactivity disorder. *Am J Psychiatry* 150:1792–1798.
- Biederman J, Mick E, Faraone SV (2000): Age-dependent decline of symptoms of attention deficit hyperactivity disorder: Impact of remission definition and symptom type. *Am J Psychiatry* 157:816–818.
- Biederman J, Mick E, Faraone SV, Braaten E, Doyle A, Spencer T, et al (2002): Influence of gender on attention deficit hyperactivity disorder in children referred to a psychiatric clinic. *Am J Psychiatry* 159:36–42.
- Bush G, Frazier JA, Rauch SL, Seidman LJ, Whalen PJ, Jenike MA, et al (1999): Anterior cingulate cortex dysfunction in attention deficit/hyperactivity disorder revealed by fMRI and the counting stroop. *Biol Psychiatry* 45:1542–1552.
- Bush G, Luu P, Posner MI (2000): Cognitive and emotional influences in anterior cingulate cortex. *Trends Cogn Sci* 4:215–222.
- Bush G, Shin LM, Holmes J, Rosen BR, Vogt BA (2003): The Multi-Source Interference Task: Validation study with FMRI in individual subjects. *Mol Psychiatry* 8:60–70.
- Bush G, Vogt BA, Holmes J, Dale AM, Greve D, Jenike MA, Rosen BR (2002): Dorsal anterior cingulate cortex: A role in reward-based decision making. *Proc Natl Acad Sci U S A* 99:523–528.
- Bussing R, Grudnik J, Mason D, Wasiak M, Leonard C (2002): ADHD and conduct disorder: An MRI study in a community sample. *World J Biol Psychiatry* 3:216–220.
- Casey BJ, Castellanos FX, Giedd JN, Marsh WL, Hamburger SD, Schubert AB, et al (1997): Implication of right frontostriatal circuitry in response inhibition and attention-deficit/hyperactivity disorder. *J Am Acad Child Adolesc Psychiatry* 36:374–383.
- Castellanos FX (1997): Toward a pathophysiology of attention-deficit/hyperactivity disorder. *Clin Pediatr* 36:381–393.
- Castellanos FX, Giedd JN, Berquin PC, Walter JM, Sharp W, Tran T, et al (2001): Quantitative brain magnetic resonance imaging in girls with attention-deficit/hyperactivity disorder. *Arch Gen Psychiatry* 58:289–295.
- Castellanos FX, Giedd JN, Eckburg P, Marsh WL, Vaituzis AC, Kaysen D, et al (1994): Quantitative morphology of the caudate nucleus in attention deficit hyperactivity disorder. *Am J Psychiatry* 151:1791–1796.
- Castellanos FX, Giedd JN, Marsh WL, Hamburger SD, Vaituzis AC, Dickstein DP, et al (1996): Quantitative brain magnetic resonance imaging in attention deficit hyperactivity disorder. *Arch Gen Psychiatry* 53:607–616.
- Castellanos FX, Lee PP, Sharp W, Jeffries NO, Greenstein DK, Clasen LS, et al (2002): Developmental trajectories of brain volume abnormalities in children and adolescents with attention-deficit/hyperactivity disorder. *JAMA* 288:1740–1748.
- Castellanos FX, Sharp WS, Gottesman RF, Greenstein DK, Giedd JN, Rapoport JL (2003): Anatomic brain abnormalities in monozygotic twins discordant for attention deficit disorder. *Am J Psychiatry* 160:1693–1696.
- Cohen J, Forman S, Braver T (1994): Activation of prefrontal cortex in a non-spatial working memory task with functional MRI. *Hum Brain Mapp* 1:293–304.
- Desmond JE, Fiez JA (1998): Neuroimaging studies of the cerebellum: Language, learning, and memory. *Trends Cogn Sci* 2:355–362.
- Dougherty DD, Bonab AA, Spencer TJ, Rauch SL, Madras BK, Fischman AJ (1999): Dopamine transporter density is elevated in patients with ADHD. *Lancet* 354:2132–2133.
- Douglas VI (1972): Stop, look and listen: The problem of sustained attention and impulse control in hyperactive and normal children. *Can J Behav Sci* 4:259–282.
- Drevets W (2000): Neuroimaging studies of mood disorders. *Biol Psychiatry* 48:813–829.
- Durston S (2003): A review of the biological bases of ADHD: What have we learned from imaging studies? *Ment Retard Dev Disabilities Res Rev* 9:184–195.
- Durston S, Hulshoff Pol HE, Schnack HG, Buitelaar JK, Steenhuis MP, Minderaa RB, et al (2004): Magnetic resonance imaging of boys with attention-deficit/hyperactivity disorder and their unaffected siblings. *J Am Acad Child Adolesc Psychiatry* 43:332–340.
- Eckert MA, Leonard CM, Richards TL, Aylward EH, Thompson J, Berninger VW (2003): Anatomical correlates of dyslexia: Frontal and cerebellar findings. *Brain* 126:482–494.
- Faraone SV, Biederman J (1998): Neurobiology of attention-deficit hyperactivity disorder. *Biol Psychiatry* 44:951–958.
- Faraone SV, Biederman J, Spencer T, Wilens T, Seidman LJ, Mick E, Doyle AE (2000): Attention deficit hyperactivity disorder in adults: An overview. *Biol Psychiatry* 48:9–20.
- Faraone SV, Perlis RH, Doyle AE, Smoller JW, Goralnick JJ, Holmgren MA, Sklar P (2005): Molecular genetics of attention deficit hyperactivity disorder. *Biol Psychiatry* 57:1313–1323.
- Filipek PA, Semrud-Clikeman M, Steingrad R, Kennedy D, Biederman J (1997): Volumetric MRI analysis: Comparing subjects having attention-deficit hyperactivity disorder with normal controls. *Neurology* 48:589–601.
- Fuster J (1989): *The Prefrontal Cortex*, 2nd ed. New York: Raven Press.
- Galaburda AM, Sherman GF, Rosen GD, Aboitiz F, Geschwind N (1985): Developmental dyslexia: Four consecutive patients with cortical anomalies. *Ann Neurol* 18:222–233.
- Gaub M, Carlson CL (1997): Gender differences in ADHD: A meta-analysis and critical review. *J Am Acad Child Adolesc Psychiatry* 36:1036–1045.
- Giedd JN, Castellanos FX, Casey BJ, Kozuch P, King AC, Hamburger SD, Rapoport JL (1994): Quantitative morphology of the corpus callosum in attention deficit hyperactivity disorder. *Am J Psychiatry* 151:665–669.
- Goldstein JM, Seidman LJ, Horton NJ, Makris N, Kennedy DN, Caviness VJ Jr, et al (2001): Normal sexual dimorphism of the adult human brain assessed by in vivo magnetic resonance imaging. *Cerebr Cortex* 11:490–497.
- Heath RG, Harper JW (1974): Ascending projections of the cerebellar fastigial nucleus to the hippocampus, amygdala, and other temporal lobe sites: Evoked potential and histological studies in monkeys and cats. *Exp Neurol* 45:268–287.
- Hechtman L (1992): Long-term outcome in attention-deficit hyperactivity disorder. *Psychiatr Clin North Am* 1:553–565.
- Hesslinger B, Tebartz van Elst L, Thiel T, Haegele K, Hennig J, Ebert D (2002): Frontoorbital volume reductions in adult patients with attention deficit hyperactivity disorder. *Neurosci Lett* 328:319–321.
- Hill DE, Yeo RA, Campbell RA, Hart B, Vigil J, Brooks W (2003): Magnetic resonance imaging correlates of attention-deficit/hyperactivity disorder in children. *Neuropsychology* 17:496–506.
- Hoge E, Friedman L, Schultz S (1999): Meta-analysis of brain size in bipolar disorder. *Schizophr Res* 37:177–181.
- Hynd GW, Hern KL, Novey ES, Eliopoulos D, Marshall R, Gonzalez JJ, Voeller KK (1993): Attention deficit-hyperactivity disorder and asymmetry of the caudate nucleus. *J Child Neurol* 8:339–347.
- Hynd GW, Semrud-Clikeman MS, Lorys AR, Novey ES, Eliopoulos D (1990): Brain morphology in developmental dyslexia and attention deficit/hyperactivity. *Arch Neurol* 47:919–926.
- Hynd GW, Semrud-Clikeman M, Lorys AR, Novey ES, Eliopoulos D, Lytinen H (1991): Corpus callosum morphology in attention-deficit hyperactivity disorder: Morphometric analysis of MRI. *J Learn Disabilities* 24:141–146.
- Kates WR, Frederikse M, Mostofsky SH, Folley BS, Cooper K, Mazur-Hopkins P, et al (2002): MRI parcellation of the frontal lobe in boys with attention deficit hyperactivity disorder or Tourette syndrome. *Psychiatry Res* 116:63–81.
- Lou H (1996): Etiology and pathogenesis of attention-deficit hyperactivity disorder (ADHD): significance of prematurity and perinatal hypoxic-haemodynamic encephalopathy. *Acta Paediatr* 85:1266–1271.
- Lyoo I, Noam G, Lee C, Lee H, Kennedy B, Renshaw P (1996): The corpus callosum and lateral ventricles in children with attention-deficit hyperactivity disorder: A brain magnetic resonance imaging study. *Biol Psychiatry* 40:1060–1063.
- Makris N, Hodge SM, Haselgrove C, Kennedy DN, Dale A, Fischl B, et al (2003): Human cerebellum: Surface-assisted cortical parcellation and volumetry with magnetic resonance imaging. *J Cogn Neurosci* 15:584–599.
- Makris N, Schlerf JE, Hodge SM, Haselgrove C, Albaugh MD, Seidman LJ, et al (in press): MRI-based surface assisted parcellation of human cerebellar cortex: An anatomically specified method with estimate of reliability. *Neuroimage*.
- Mannuzza S, Klein RG, Bessler A, Malloy P, LaPadula M (1993): Adult outcome of hyperactive boys: Educational achievement, occupational rank and psychiatric status. *Arch Gen Psychiatry* 50:565–576.

- Mataro M, Garcia-Sanchez C, Junque C, Estevez-Gonzalez A, Pujol J (1997): Magnetic resonance imaging measurement of the caudate nucleus in adolescents with attention-deficit hyperactivity disorder and its relationship with neuropsychological and behavioral measures. *Arch Neurol* 54:963–968.
- Mattes JA (1980): The role of frontal lobe dysfunction in childhood hyperkinesis. *Compr Psychiatry* 21:358–369.
- Mesulam MM (1990): Large-scale neurocognitive networks and distributed processing for attention, language and memory. *Ann Neurol* 28:597–613.
- Middleton FA, Strick PL (2001): Cerebellar projections to the prefrontal cortex of the primate. *J Neurosci* 21:700–712.
- Mostofsky S, Cooper K, Kates W, Denckla M, Kaufmann W (2002): Smaller prefrontal and premotor volumes in boys with attention-deficit/hyperactivity disorder. *Biol Psychiatry* 52:785–794.
- Mostofsky SH, Reiss AL, Lockhart P, Denckla MB (1998): Evaluation of cerebellar size in attention-deficit hyperactivity disorder. *J Child Neurol* 13:434–439.
- Nopolous P, Berg S, Castellanos FX, Delgado A, Andreasen NC, Rapoport JL (2000): Developmental brain anomalies in children with attention-deficit hyperactivity disorder. *J Child Neurol* 15:102–108.
- O'Kusky J, Strauss E, Kosaka B, Wada J, Li D, Druhan M, Petrie J (1988): The corpus callosum is larger with right-hemisphere cerebral speech dominance. *Ann Neurol* 24:379–383.
- Overmeyer S, Bullmore ET, Suckling J, Simmons A, Williams SC, Santosh PJ, Taylor E (2001): Distributed grey and white matter deficits in hyperkinetic disorder: MRI evidence for anatomical abnormality in an attentional network. *Psychol Med* 31:1425–1435.
- Overmeyer S, Simmons A, Santosh J, Andrew C, Williams SCR, Taylor A, et al (2000): Corpus callosum may be similar in children with ADHD and siblings of children with ADHD. *Dev Med Child Neurol* 42:8–13.
- Paus T, Koski L, Caramanos Z, Westbury C (1998): Regional differences in the effects of task difficulty and motor output on blood flow response in the human anterior cingulate cortex: A review of 107 PET activation studies. *Neuroreport* 9:R37–R47.
- Pennington BF, Ozonoff S (1996): Executive functions and developmental psychopathology. *J Child Psychol Psychiatry* 37:51–87.
- Pineda DA, Restrepo A, Sarmiento RJ, Gutierrez JE, Vargas SA, Quiroz YT, Hynd GW (2002): Statistical analyses of structural magnetic resonance imaging of the head of the caudate nucleus in Colombian children with attention-deficit hyperactivity disorder. *J Child Neurol* 17:97–105.
- Posner MI, Petersen SE (1990): The attention system of the human brain. *Annu Rev Neurosci* 13:25–42.
- Rumsey J, Casanova M, Mannheim GB, Patronas N, De Vaughn N, Hamburger SD, Aquino T (1996): Corpus callosum morphology, as measured with MRI, in dyslexic men. *Biol Psychiatry* 39:769–775.
- Schmahmann JD (1994): The cerebellum in autism: clinical and anatomic perspectives. In: Bauman ML, Kemper TL, eds. *The Neurobiology of Autism*. Baltimore, MD: John Hopkins University Press, 195–226.
- Schmahmann JD (2001): The cerebrocerebellar system: Anatomic substrates of the cerebellar contribution to cognition and emotion. *Int Rev Psychiatry* 13:247–260.
- Schmahmann JD, Sherman JC (1998): The cerebellar cognitive affective syndrome. *Brain* 121:561–579.
- Seidman LJ, Biederman J, Faraone SV, Milberger S, Norman D, Seiverd K, et al (1995): Effects of family history and comorbidity on the neuropsychological performance of children with ADHD: Preliminary findings. *J Am Acad Child Adolesc Psychiatry* 34:1015–1024.
- Seidman LJ, Biederman J, Monuteaux MC, Doyle A, Faraone SV (2001): Learning disabilities and executive dysfunction in boys with attention deficit hyperactivity disorder. *Neuropsychology* 15:544–556.
- Seidman LJ, Biederman J, Weber W, Hatch M, Faraone SV (1998): Neuropsychological function in adults with attention-deficit hyperactivity disorder. *Biol Psychiatry* 44:260–268.
- Seidman LJ, Doyle A, Fried R, Valera E, Crum K, Matthews L (2004b): Neuropsychological function in adults with attention-deficit hyperactivity disorder. *Psychiatr Clin North Am* 27:261–282.
- Seidman LJ, Pantelis C, Keshavan MS, Faraone SV, Goldstein JM, Horton NJ, et al (2003): A review and a new report of medial temporal lobe dysfunction as a vulnerability indicator for schizophrenia: A magnetic resonance imaging morphometric family study of the parahippocampal gyrus. *Schizophr Bull* 29:803–828.
- Seidman LJ, Valera E, Bush G (2004a): Brain function and structure in adults with attention-deficit hyperactivity disorder. *Psychiatr Clin North Am* 27:323–347.
- Semrud-Clikeman MS, Biederman J, Sprich S, Krifcher B, Norman D, Faraone S (1992): Comorbidity between ADHD and learning disability: A review and report in a clinically referred sample. *J Am Acad Child Adolesc Psychiatry* 31:439–448.
- Semrud-Clikeman MS, Filipek PA, Biederman J, Steingard R, Kennedy D, Renshaw P, Bekken K (1994): Attention-deficit hyperactivity disorder: Magnetic resonance imaging morphometric analysis of the corpus callosum. *J Am Acad Child Adolesc Psychiatry* 33:875–881.
- Semrud-Clikeman M, Steingard RJ, Filipek P, Biederman J, Bekken K, Renshaw PF (2000): Using MRI to examine brain-behavior relationships in males with attention deficit disorder with hyperactivity. *J Am Acad Child Adolesc Psychiatry* 39:477–484.
- Shaywitz S (1998): Dyslexia. *New Engl J Med* 338:307–312.
- Shaywitz BA, Klopfer JH, Gordon JW (1978): Methylphenidate in G-hydroxydopamine treated developing rat pups. *Child Neurol* 35:463–467.
- Sowell ER, Thompson PM, Welcome SE, Henkenius AL, Toga AW, Peterson BS (2003): Cortical abnormalities in children and adolescents with attention-deficit hyperactivity disorder. *Lancet* 362:1699–1707.
- Sprich-Buckminster S, Biederman J, Milberger S, Faraone S, Krifcher Lehman B (1993): Are perinatal complications relevant to the manifestation of ADD? Issues of comorbidity and familiarity. *J Am Acad Child Adolesc Psychiatry* 32:1032–1037.
- Still G (1902): The Coulstonian lectures on some abnormal physical conditions in children. Lecture 1. *Lancet* 1008–1012, 1077–1082, 1163–1168.
- Volkow ND, Fowler JS, Wang GJ, Ding YS, Gatley SJ (2002): Role of dopamine in the therapeutic and reinforcing effects of methylphenidate in humans: Results from imaging studies. *Eur Neuropsychopharmacol* 12:557–566.
- Weiss G, Hechtman LT (1986): *Hyperactive Children Grown Up*. New York: Guilford Press.
- Witelson S (1989): Hand and sex differences in isthmus and genu of the human corpus callosum: A postmortem morphological study. *Brain* 112:799–835.
- Zametkin AJ, Nordahl TE, Gross M, King AC, Semple WE, Rumsey J, et al (1990): Cerebral glucose metabolism in adults with hyperactivity of childhood onset. *New Engl J Med* 323:1361–1366.